



Dyspeptic symptoms should be examined on time - using Finnish innovations

Dyspeptic symptoms are common in Finland, and particularly among elderly people, these can be of Helicobacter (Hp) origin. Hp-induced or autoimmune-type atrophic gastritis (atrophy of the stomach mucosa) is asymptomatic and remains frequently undetected in the primary diagnosis of dyspeptic and reflux symptoms. Gastric cancer developing from Hp-related atrophic gastritis (AG) is diagnosed in most cases too late when the patient already has alarming symptoms. GastroPanel- and ColonView-FIT- innovations of a Finnish biotechnology company Biohit Oyj may expedite the timely diagnosis.

Dyspeptic symptoms are affecting some 20-40 per cent of people in Finland. Part of the symptoms represent harmless functional disorders, but particularly among the older age groups, Hp-induced AG is not uncommon. AG together with low gastric acid output increases the risk of gastric- and esophageal cancer. Nearly 1000 new cases of these cancers are diagnosed each year, with some 700 cancer deaths. Gastroscopy and biopsy examination are often performed only when the alarming symptoms appear and the disease outlook in most cases is ominous.

Screening and timely use of innovative tests for daily routine

Hp-tests recommended by the current guidelines do not aid in diagnosis of AG or abnormal gastric acid output. Biohit GastroPanel test results are interpreted by special software application (GastroSoft), which integrates the clinical information with the biomarker values giving comprehensive and accurate view on gastric mucosal structure and its function.

If this combination would be used for screening of the gastric- and esophageal cancer risk e.g. among 65-74-year-old subjects (10 age groups), around 600 000

people, one would obtain valuable diagnostic information, and in addition, would achieve savings in life-time health care costs by around 800 million euros.

Particularly among elderly people, upper abdominal symptoms can be of intestinal origin. Biohit ColonView-FIT helps in early detection of colorectal cancer precursor lesions. Patient safety would be increased if also the intestinal status would be examined as an integral part of the management of upper abdominal symptoms.

Along with the rapid technological progress, these tests should absolutely be included in the primary diagnosis of dyspepsia and reflux symptoms nationwide as well as in screening, to improve patient safety and avoid increased costs and even unnecessary cancer deaths.

Acetium might decrease the cancer risk

AG or long-term PPI treatment result in acid-free stomach, which is associated with e.g. an increased risk of gastric cancer. Current evidence supports and even favors the concept that this risk might be possibly reduced by eliminating carcinogenic acetaldehyde borne in acid-free stomach with Acetium capsules developed by Biohit Oyj.

Atrophic gastritis:

An underdiagnosed risk of gastric cancer and a cause of multi-deficiency syndromes

One disease – two causative factors

Atrophic gastritis (AG) is a progressive atrophy of the stomach mucosa, with two diverse etiological factors:

Helicobacter pylori (Hp)-infection and autoimmune mechanism (1). Autoimmune-type AG is clearly associated with other autoimmune diseases, being more common than in general population e.g. among patients with type 1 diabetes mellitus (DM1) and autoimmune thyroid disease (AITD) (2). Much of the current understanding on the natural history of chronic gastritis/AG and their association with the most important gastric disorders owes to a Finnish-Estonian collaboration between the research groups of professors Max Siurata and Kaljo Villako, continued since the 1960's and 1970's. GastroPanel-innovation of Biohit Oyj continues this tradition in Finland (www.biohithealthcare.com/additional-information).

Prevalence of Hp-infection coincides that of AG

The frequency of Hp-infection among the population is directly related to the prevalence of AG; e.g. in the former eastern bloc countries, where Hp-prevalence exceeds 70% in a population-based screening (mean age 50yrs), AG is detected in up to 15% of the study subjects (3,4). Similar AG prevalence rates in countries with low Hp-risk are reached only in the oldest age groups: in a Finnish cohort with the mean age of 82 years, the prevalence of Hp-infection was 24%, and AG was diagnosed in 12.3% of the subjects (5), falling within the same range as among a random sample of DM1- and AITD-patients (2). According to the most recent evidence, it seems possible that *Helicobacter pylori* itself might be one of the triggers of the autoimmune mechanism leading to AG (6). It has been estimated that approximately one half of the world population are carriers of Hp-infection, and the resulting AG is affecting up to 500 million people worldwide.

Conventional Hp-tests, 13C urea breath test, stool antigen test and stand-alone Hp-antibody tests, do not detect AG and also fail to disclose the aberrations in gastric acid output (26). Failure to diagnose these risk factors on time, gastric- and esophageal cancer is detected in most cases only when alarming symptoms appear. Nearly 1000 new cases of these cancers are diagnosed each year in Finland, with some 700 cancer deaths. Along with the aging population, the disease burden of AG and its sequels in the national health care is steadily increasing also in Finland (5,11,14-17).

The risk of pneumonia and even fatal intestinal infections, e.g. giardiasis and *Clostridium difficile*, is shown to be significantly increased among elderly people when the stomach is acid-free. Therefore, it is possible that AG (acid-free stomach) with its

sequels might predispose particularly these senior citizens to coronavirus infection and its more severe clinical outcome (27-30).

Atrophic gastritis: correct classification and grading are important

AG is classified on the basis of its topographic site as antrum (AGA)-, corpus (AGC)- or pan-atrophy (AGpan), according to which site of the stomach mucosa is affected (Figure 1). For classification of gastritis, so called USS (Updated Sydney System) classification is commonly used (7), which emphasizes, in addition to their grading of severity (mild, moderate, severe), also the importance of "gastritis phenotyping", (AGA, AGC, AGpan). The reasons become obvious in Figure 2.

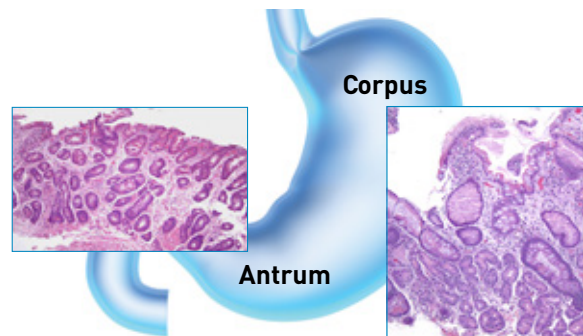


Figure 1. Atrophy in the antrum and in the corpus

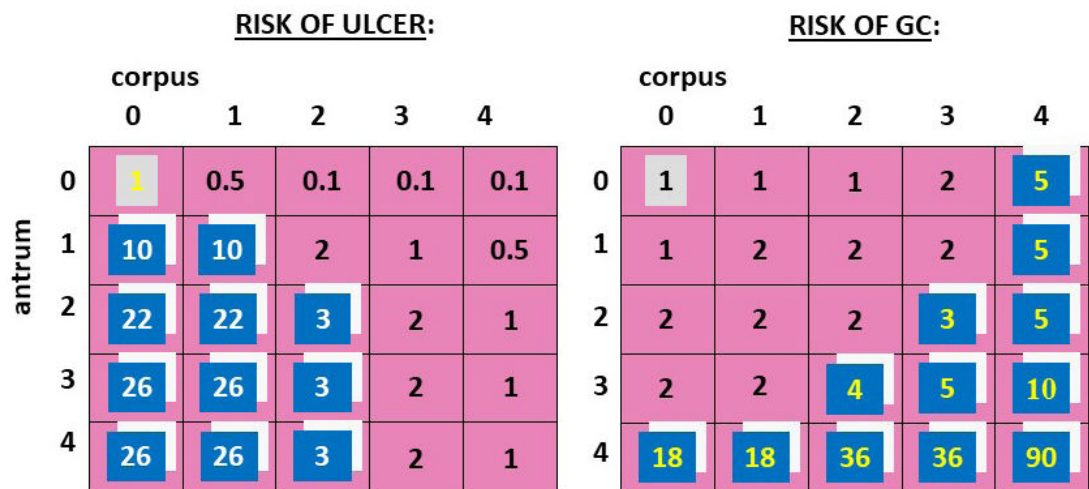
AGA and AGC: topography and grade determine the future risk

Accordingly (Figure 2), severe AGA significantly ($OR > 25$) increases the risk of peptic ulcer disease, whereas severe AGC is a significant risk condition for gastric cancer. In the most severe combination (severe AGA and severe AGC), the risk of gastric cancer is 90-fold as compared with the healthy stomach (8). Because of this, it is important to make distinction between AGA and AGC. Currently, this can be done without invasive gastroscopy and biopsies, using non-invasive biomarker test (GastroPanel®, Biohit Oyj), that also detects Hp-infection (9,10).

Natural history of chronic gastritis: Correa's cascade

The clinical course of AG has been exhaustively documented in longitudinal studies initiated in the 1960's in Finland (8,11). Mucosal atrophy develops during years and decades without causing clinical symptoms, and because of this, the diagnosis is frequently delayed (10). At worst, the correct diagnosis is reached only at the stage when the patient already has alarming symptoms and when the disease process starting from Hp-infection. i.e., Correa's cascade, (Figure 3) (12) has already progressed to gastric cancer and frequently beyond reach of a curative therapy

Phenotype of gastritis – the diagnosis that matters!



0=normal; 1=non-atrophic gastritis; 2=mild AG, 3=moderate AG, 4=severe AG

Sipponen et al. Int J Cancer 1985
Scand J Gastroenterol 1989

Figure 2. The risk profile is different for AGA and AGC

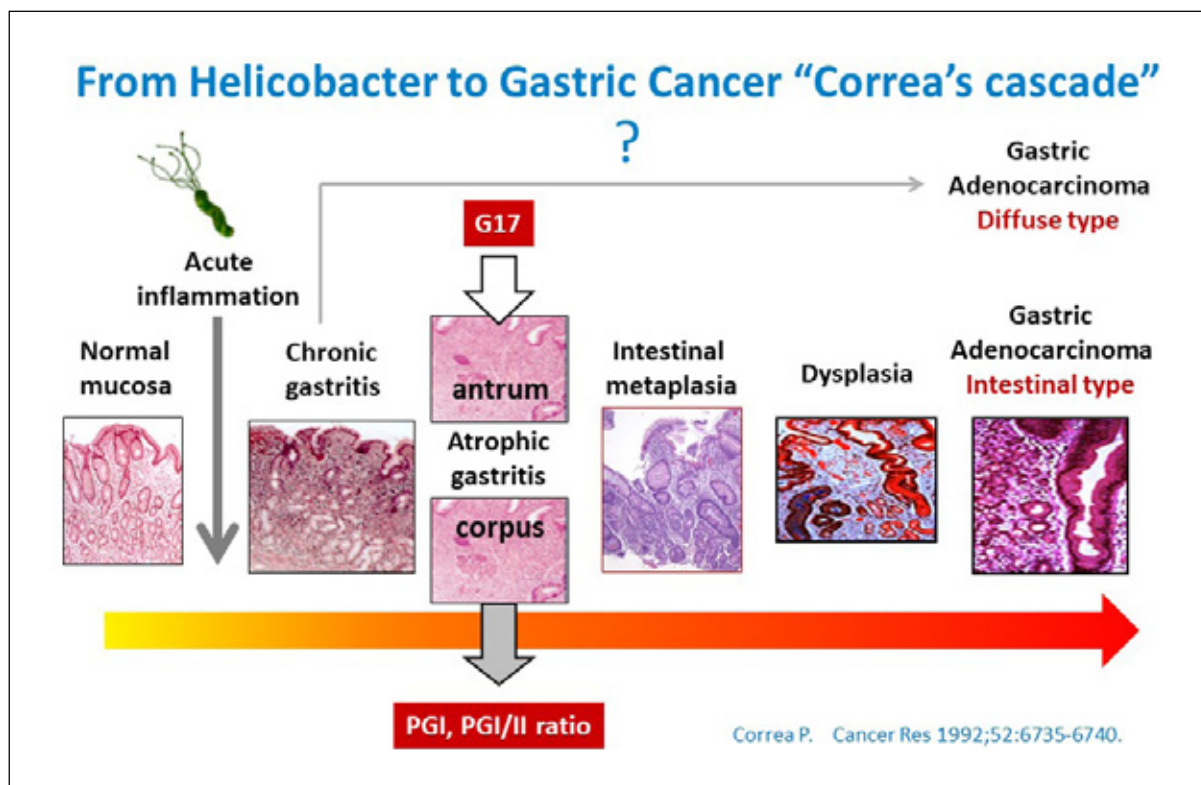


Figure 3. Pathogenesis of gastric cancer ("Correa's cascade")

AG-a common denominator of multi-deficiency syndromes

The clinical importance of AG is not only limited to an increased risk of gastric cancer (8,10), but atrophy of the stomach mucosa is known to lead to malabsorption and deficiency of several key trace

elements of the body homeostasis resulting in chronic deficiency states (11,13). In particular, AG of the stomach body (AGC) causes malabsorption of vitamin-B12, iron, calcium, zinc and magnesium, and in addition, impairs mucosal absorption of several medicines (14-17). The best known

deficiency states caused by AG include pernicious anemia, iron-deficiency anemia and osteoporosis, and less well known vitamin B12-deficiency-related conditions include dementia, depression, peripheral neuropathy and Alzheimer's disease [5,11,14-17]. Along with population aging, the disease burden of these AG-related sequels in the national health care is steadily increasing also in Finland [5,11,14-17]. A suspicion has been raised that AG with its sequels might predispose particularly the elderly people to coronavirus infections and/or to its more severe clinical outcome [27-30].

Conventional Hp-tests do not detect AG, masking its risks

Based on the above listed reasons, early diagnosis of AG is extremely important, irrespective of its etiological cause (Hp, autoimmune-type). The possibility of an autoimmune-type AG should be kept in mind whenever the patient has been diagnosed with any other autoimmune disease [2,5], because the risk of AG in these patients is markedly increased. Helicobacter pylori diagnosis based on the traditional tests: 13C urea breath test (UBT) and stool antigen test (SAT), is not reliable, because both UBT and SAT tests may give false negative results in up to 40% of cases [18]. UBT may also give false positive results when the stomach is acid-free. Furthermore, one should emphasize that UBT and SAT or stand-alone Hp-antibody test, do not detect AG, and the associated risks remain undisclosed with these tests [19 -23]. In addition to AG, GastroPanel® test will measure the state of gastric acid output, which is not accomplished by conventional Hp-tests or gastroscopy [26].

Persistent high acid output predisposes to esophageal reflux disease, which might be accompanied by erosive esophagitis, Barrett's esophagus or lower esophageal cancer.

Screening of AG cannot be based on invasive endoscopy

Traditionally, AG has been diagnosed by histological biopsies taken on endoscopy (gastroscopy) (Figure 1). Given that the prevalence of AG at the population level may exceed 15%, an invasive and expensive gastroscopy that requires considerable clinical skills, is not an optimal method for a population-based screening for AG [10]. As also known that i) AG may be the causative factor for upper abdominal symptoms (dyspepsia) [11], and ii) the prevalence of dyspepsia in the population is around 20-40%, it is clear that the diagnosis and screening of AG can only be realized by using a non-invasive test [10].

Precise diagnosis is possible by serological biomarker test (GastroPanel®)

In parallel with the increasing understanding on the natural history of AG [8,11] and the causative factors behind dyspepsia, also the global recognition of the shortcoming associated with the invasive diagnostic techniques has been crystallized. To find alternative tests, increased attention was paid to single stomach-specific biomarkers analyzed in blood samples as potential diagnostic tools for gastric function since the 1980's, first in Japan. It was in Finland, however, where the scientists first succeeded in developing a combination (panel) of biomarkers that gives a global view on both the structure and function of the stomach from

GastroPanel® – interpretation guide snapshot

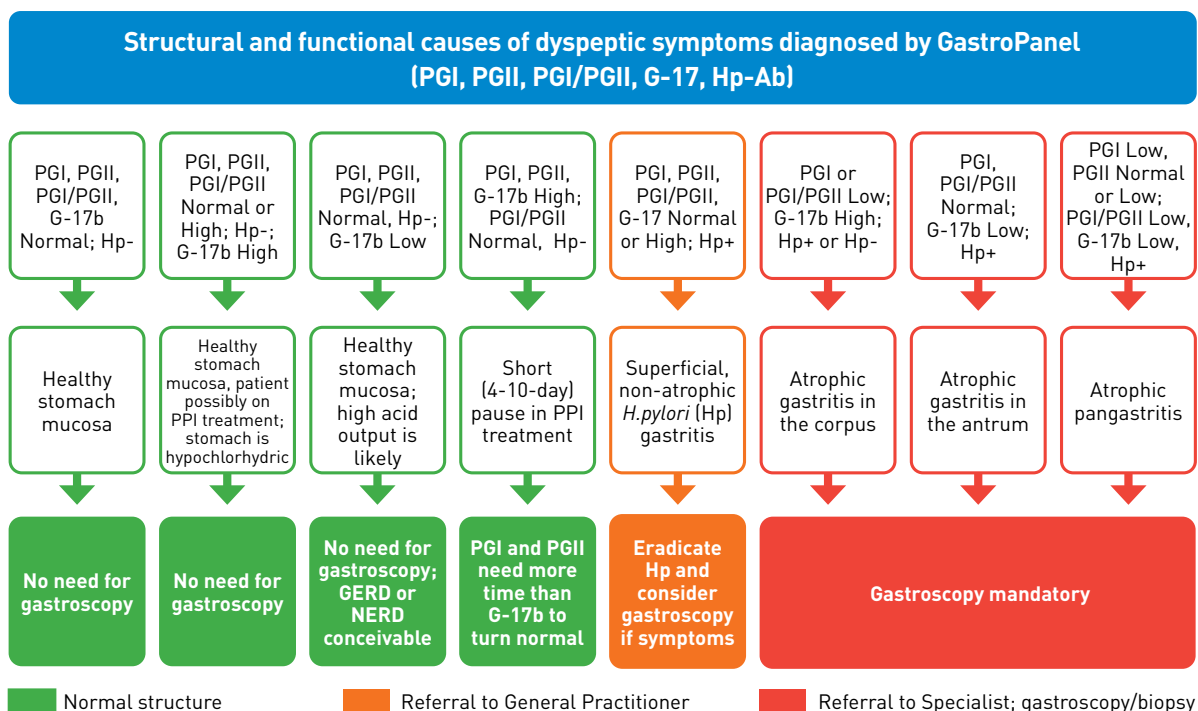


Figure 4. Biomarker profiles of the GastroPanel-test

a single blood test (www.biohithealthcare.com/additional-information). The test was developed by a Finnish Biohit Oyj, and the novel test was named as GastroPanel® that accurately describes its capabilities (9,19,20) (www.gastropanel.com).

By combining the profiles of the four GastroPanel® biomarkers (pepsinogen I, pepsinogen II, gastrin-17 and Hp IgG ELISA) (Figure 4) with the recorded simple clinical information of the patient, GastroSoft® application provides the diagnosis as a printed output (Figure 5).

Biomarker profiles aid in risk stratification and selection of appropriate clinical actions

The eight biomarker profiles of GastroPanel® test give a comprehensive view on stomach functions and its mucosal structure. In Figure 4, the profiles in green represent functional disorders, with normal mucosal structure in each and no special actions are needed. The prolife in orange denotes Hp-infection, which according to current guidelines, requests an eradication treatment and its control within the primary health care. Those three profiles printed in red represent AG, stratified by topography: AGA, AGC, AGpan. The color is red because it should act as a warning signal to the recipient of the report

in that the patient should be referred (without delay) to gastroscopy to confirm the grade of AG in the biopsies (7,11).

Reliable results are provided only by the GastroSoft® application

GastroSoft® software application has been designed exclusively for interpretation of GastroPanel® test results. To confirm the correct diagnosis, equally important as the biomarker profiles (Figure 4) is also the simple clinical information recorded from the patient before sampling; if missed, the interpretation of the test results remains ambiguous. Because of the fact that certain biomarker profiles do have more than one explanation, GastroPanel® test results must always be interpreted by using the GastroSoft® application, instead of a single visual inspection of the individual biomarker values (9,19,20).

GastroPanel® test has been validated in two meta-analyses

The first generation of GastroPanel® test was introduced in the early years of 2000's (9,19,20), and the latest version of the test passed the clinical validation studies just recently (2,21). GastroPanel® test is the first-on-market and still the only non-

BIOHIT HealthCare
Innovating for Health

Patient Data
Patient id
Patient age
Gender

Eradicated: **No**
Use of PPI: **Occasionally**
Acid symptoms: **No**
Use of NSAIDs: **No**

Sample data
Collection time
Analysis time

Laboratory analysis results		Reference range
Pepsinogen I	27.5 µg/l *	30-160 µg/l
Pepsinogen II	19.1 µg/l *	3-15 µg/l
Pepsinogen I/II	1.4 *	3-20
Gastrin 17B (fasting)	9.2 pmol/l *	1-7 pmol/l
<i>H.pylori</i>	164 EIU *	<30 EIU

Interpretation
The results indicate atrophic corpus gastritis (loss of gastric cells) due to a *Helicobacter pylori* infection. Gastric acid secretion is decreased. Atrophic gastritis (loss of gastric cells, "no gastric acid") is a significant risk factor for gastric cancer. Hence gastroscopy is recommended. The carcinogenic acetaldehyde forming in an achlorhydric stomach is most likely the cause of gastric and oesophageal cancer. The final diagnosis can be decided after gastroscopy.

Notice! The final diagnosis shall always be made by the clinician/medical doctor.

Figure 5. GastroSoft-output (typical atrophic gastritis of the corpus)

invasive diagnostic test for Hp-infection and AG. As such, the test has aroused widespread global interest since the very beginning, and its use has been recommended by an authoritative expert panel already in 2012 (10). Even before that, in 2006, an international "Gastritis Consensus Workshop" presided by professor Shu-Dong Xiao in Shanghai (China), and participated e.g. by professors Pelayo Correa (USA) and Pentti Sipponen (Finland), decided to adopt GastroPanel® test for use within Chinese health care [www.biohithealthcare.com / News/ Links: Dear Colleague 2006](http://www.biohithealthcare.com/News/Links:DearColleague2006)).

The performance and reliability of GastroPanel® test has been evaluated in several large-scale clinical trials worldwide, using different study settings: gastroscopy referral (symptomatic) patients, screening settings (asymptomatic subjects), different risk groups, longitudinal settings (detailed review in reference 22). All published studies were included in two systematic reviews and subjected to meta-analysis (23,24). The results of both these mutually independent meta-analyses were concordant: the pooled (all studies included) sensitivity and specificity of GastroPanel® test in detecting biopsy-confirmed moderate/severe AG (AG2+) was of the order of 75% and 95%, respectively (23,24). In the clinical validation studies of the new-generation GastroPanel® test (2,21), the performance indicators exceeded even those of the meta-analyses, when pepsinogen I detected AG2+ endpoint (ROC analysis) with AUC=0.939 (2) and Hp IgG ELISA found biopsy-confirmed Hp-infection with AUC=0.978 precision (21). It is hard to imagine higher performance indicators for any currently available laboratory test.

Conclusions

Atrophic gastritis (AG) may be caused by Hp-infection or autoimmune mechanism. On the global scale, the former is by far the more common, and the prevalence of Hp closely correlates with the prevalence of AG in the population. AG is the most important risk condition for gastric cancer, and its Hp-initiated pathogenesis is well known (Correa's cascade). In particular, AG of the gastric body (corpus) results in malabsorption of several key trace elements needed in body homeostasis, with severe deficiency states as a consequence.

AG is problematic in that the vast majority is asymptomatic or associated with non-specific symptoms only, and because of this AG is clearly an underdiagnosed entity also in Finland (5,11,38-40). Similar as in all latent diseases, the key to correct diagnosis is a sound suspicion. If the patient does not present with alarming symptoms, the primary diagnosis of AG does no longer necessitate endoscopy and biopsy examination, but AG can be detected using a simple blood test (GastroPanel®). The four biomarker levels measured by GastroPanel® test are integrated

with the simple clinical information by using the GastroSoft® application. On the basis of the results, the study subjects can be stratified into three levels with a different risk: 1) healthy stomach, 2) Hp-infection, and 3) AG; which dictates the required clinical actions. As the fourth 4) group, the test can distinguish the patients with symptomatic high acid output, which is another indication for gastroscopy referral (22) (www.biohithealthcare.com/additional-information).

The principal indications of GastroPanel® test use are 1) the first-line diagnosis of the patients with dyspeptic or reflux symptoms (to find out the patient who benefit from gastroscopy) as well as 2) screening of asymptomatic subjects for detection of the risk conditions of gastric- and esophageal cancer (Hp, AG and high acid output). Because only the subjects at risk level 3) and 4) (=AG and symptomatic high acid output) benefit from gastroscopic examination, use of GastroPanel® test makes possible to avoid up to 80% of unnecessary gastroscopies (5,11,22). Using a modelling approach, it was estimated that in Finland, it is possible to save up to 800 million euro in the life-time health care costs simply by systematic screening of e.g. all 65-74-year-old (10 age groups) by GastroPanel® test (25).

Biohit's recommendations

GastroPanel- ja ColonView-FIT- tests are recommended as the first-line diagnostic tests for the patients with dyspeptic and reflux symptoms, to increase patient safety and to achieve cost savings (25, 26). GastroPanel might be a useful adjunct in coronavirus testing of elderly people, because, in most cases, asymptomatic AG (with all its potential sequels) might predispose these senior citizens also to coronavirus infection and/or to more severe forms of the disease (27-30).

In addition, it is recommended that the current best practice guidelines (dyspepsia and reflux disease) should be updated e.g. by replacing the traditional and problematic Hp-tests (UBT and SAT) by GastroPanel-examination (10,11,23,24,26,37-41, [www.biohithealthcare.com / News/Links: Dear Colleague 2006](http://www.biohithealthcare.com/News/Links:DearColleague2006) and GastroPanel innovation).

In its laboratory directory, HUSLAB announces the following indications for the "stomach biomarker examination" (GastroPanel):

"The tests are used in the diagnostic set-up of the patients with abdominal complaints, in diagnosis of Helicobacter infection, and in early detection of atrophic gastritis" (37).

AG and long-term use of PPI medication lead to acid-free stomach, which may be associated for example with increased risk of gastric cancer. Emerging evidence suggests that such a risk could be reduced by eliminating carcinogenic acetaldehyde borne in acid-free stomach using Acetium-capsules.

References:

1. Lahner E, Conti L, Annibale B. et al. Current perspectives in atrophic gastritis. *Curr Gastroenterol Rep* 2020;22(8):38. doi: 10.1007/s11894-020-00775-1.
2. Koivurova O-P, Ukkola O, Koivikko M, et al. Screening of the patients with autoimmune thyroid disease (AITD) and type 1 diabetes mellitus (DM1) for atrophic gastritis (AG) by serological biomarker testing (GastroPanel®). *EC Gastroenterol Digest Syst* 2020;7(9): 181-195.
3. Benberin V, Bektayeva R, Karabayeva R, et al. Prevalence of H.pylori infection and atrophic gastritis among asymptomatic and dyspeptic adults in Kazakhstan. A Hospital-based screening with a panel of serum biomarkers. *Anticancer Res* 2013;33:4595-4602.
4. Roman LD, Lukyanchuk R, Sablin OA, et al. Prevalence of infection and atrophic gastritis in a population-based screening with serum biomarker panel (GastroPanel®) in St. Petersburg. *Anticancer Res* 2016;36:4129-4138.
5. Aine R, Kahar E, Aitokari K, et al. Atrophic gastritis (AG) and its clinical sequels among elderly people in Finland and Estonia. A comparative study using GastroPanel and B12-vitamin testing of the residents in assisted-housing facilities. *J Aging Res Clin Pract* 2016;5:194-202.
6. Youssefi M, Tafaghodi M, Farsiani H. et al. Helicobacter pylori infection and autoimmune diseases; Is there an association with systemic lupus erythematosus, rheumatoid arthritis, autoimmune atrophy gastritis and autoimmune pancreatitis? A systematic review and meta-analysis study. *J Microbiol Immunol Infect* 2020;S1684-1182(20)30209-7. doi: 10.1016/j.jmii.2020.08.011.
7. Dixon MF, Genta RM, Yardley JH et al. Classification and grading of gastritis. The updated Sydney System. International Workshop on the Histopathology of Gastritis, Houston 1994. *Am J Surg Pathol* 1996;20(10):1161-1181.
8. Sipponen P, Kekki M, Haapakoski J, et al. Gastric cancer risk in chronic atrophic gastritis: statistical calculations of cross-sectional data. *Int J Cancer* 1985;35(2):173-177.
9. <http://www.gastropanel.com>
10. Agréus L, Kuipers EJ, Kupcinskas L, et al. Rationale in diagnosis and screening of atrophic gastritis with stomach-specific plasma biomarkers. *Scand J Gastroenterol* 2012;47(12):136-147.
11. Sipponen P, Härkönen M, Salaspuro M. Atrofinen gastriitti jää usein liian vähälle huomiolle. *Suomen Lääkärilehti* 63(15):1428-1430, 2008.
12. Correa P. Human gastric carcinogenesis: A multistep and multifactorial process. First American Cancer Society Award Lecture on Cancer Epidemiology and Prevention. *Cancer Res* 1992;52(24):6735-6740.
13. Varis K. Surveillance of pernicious anemia. In: Precancerous Lesions of the Gastrointestinal Tract. Scherlock P, Morson PC, Barbara L, Veronesi U (eds), Raven Press, New York, 1983;pp. 189-194.
14. Sipponen P, Laxén F, Huotari K, et al. Prevalence of low vitamin B12 and high homocysteine in serum in an elderly male population: association with atrophic gastritis and Helicobacter pylori infection. *Scand J Gastroenterol* 2003;38:1209-1216
15. Sipponen P, Härkönen M. Hypochlorhydric stomach: a risk condition for calcium malabsorption and osteoporosis? *Scand J Gastroenterol* 2010;45:133-138.
16. Stabler S. Vitamin B12 deficiency. *N Engl J Med* 2013;368:149-160.
17. Bolander-Gouaille C. Focus on Homocysteine and the Vitamins involved in its Metabolism. Berlin: Springer Verlag. 2002.
18. Gurbuz AK, Ozel AM, Narin Y, et al. Is the remarkable contradiction between histology and 14C urea breath test in the detection of Helicobacter pylori due to false-negative histology or false-positive 14C urea breath test? *J Int Med Res* 2005;33(6):632-640.
19. Suovaniemi O. GastroPanel®-tutkimus osaksi dyspepsian hoitokäytäntöä. *Yleislääkäri* 2007;4:104-106.
20. www.biohithealthcare.com/News/Links: Suovaniemi O, State of the art GastroPanel® and Acetium® innovations for the unmet need. *Terveyspalvelut* 2011;3-4: 1-12.
21. Mäki M, Söderström D, Paloheimo L, et al. Helicobacter pylori (Hp) IgG ELISA of the new-generation GastroPanel® is highly accurate in diagnosis of Hp-Infection in gastroscopy referral patients. *Anticancer Res* 2020;40:6387-6398.
22. Syrjänen K, Eskelinen M, Peetsalu A, et al. GastroPanel® Biomarker Panel: The most comprehensive test for Helicobacter pylori infection and its clinical sequelae. A critical review. *Anticancer Res* 2019;39:1091-1104.
23. Syrjänen K. A Panel of serum biomarkers (GastroPanel®) in non-invasive diagnosis of atrophic gastritis. Systematic review and meta-analysis. *Anticancer Res* 2016;36:5133-5144.
24. Zagari RM, Rabitti S, Greenwood DC, et al. Systematic review with meta-analysis: Diagnostic performance of the combination of pepsinogen, gastrin-17 and anti-Helicobacter pylori antibodies serum assays for the diagnosis of atrophic gastritis. *Aliment Pharmacol Ther* 2017;46:1-11.

25. <https://www.gastropanel.com/decision-makers/screening-model>
26. <https://www.biohithealthcare.com/wp-content/uploads/2019/11/Criticism-about-current-care-recommendations.pdf>
27. [www.biohithealthcare.com /About Us /Investors/Stock Exchange Releases: 2020-04-15T07:03:40Z – Does an undiagnosed atrophic gastritis \(acid-free stomach\) increase the risk of coronavirus infection, its complications and mortality particularly among elderly people?](http://www.biohithealthcare.com/About%20Us/Investors/Stock%20Exchange%20Releases%202020-04-15T07:03:40Z-Does%20an%20undiagnosed%20atrophic%20gastritis%20(acid-free%20stomach)%20increase%20the%20risk%20of%20coronavirus%20infection,%20its%20complications%20and%20mortality%20particularly%20among%20elderly%20people%3F)
28. Lee SW, et al. Severe clinical outcomes of COVID-19 associated with proton pump inhibitors: a nationwide cohort study with propensity score matching *Gut* 2020;0:1–9. doi:10.1136/gutjnl-2020-322248
29. Stein RA. COVID-19: Risk groups, mechanistic insights and challenges. *Int J Clin Pract.* 2020;74:e13512
30. [www.biohit.healthcare.com /News/Links: Shareholders' Meeting 2020 \(Osmo Suovaniemi\)](http://www.biohit.healthcare.com/News/Links:Shareholders%20Meeting%202020%20(Osmo%20Suovaniemi))
31. Salaspuro M. Acetaldehyde as a common denominator and cumulative carcinogen in digestive tract cancers. *Scand J Gastroenterol* 2009; 44:912-25.
32. Seitz HK, Stickel F. Acetaldehyde as an underestimated risk factor for cancer development: role of genetics in ethanol meta-bolism. *Genes Nutr* 2010;5:121-128.
33. Jeong Soo Ahn, Chun-Sick Eom, Christie Y Jeon, Sang Min Park. Acid suppressive drugs and gastric cancer: A meta-analysis of observational studies. *World J Gastroenterol* 2013 April 28; 19(16): 2560-2568.
34. Hellström PM, Hendolin P, Kaihovaara P, Kronberg L, Meierjohann A, Millerhov A, Paloheimo L, Sundelin H, Syrjänen K, Webb D-L, Salaspuro M. Slow-release L-cysteine capsule prevents gastric mucosa exposure to carcinogenic acetaldehyde: results of a randomised single-blinded, cross-over study of Helicobacter-associated atrophic gastritis. *Scand. J. Gastroenterol* 2016;52:230-237.
35. Lachenmeier DW, Salaspuro M. ALDH2-deficiency as genetic epidemiologic and biochemical model for the carcinogenicity of acetaldehyde. *Regul Toxicol Pharmacol.* 2017;86:128-136.
36. [www.biohithealthcare.com/ About Us /Investors/Stock Exchange Releases: 2017-09-11T07:30:00Z – An important patent granted to Biohit Acetium® Capsule in Japan](http://www.biohithealthcare.com/About%20Us/Investors/Stock%20Exchange%20Releases:2017-09-11T07:30:00Z-Important%20patent%20granted%20to%20Biohit%20Acetium%20Capsule%20in%20Japan)
37. [http://www.huslab.fi/Tutkimusohjekirja haulla helikobakteeri: 20609 fP-Mabi-La fP-Mahalaukun biomerkkiainetutkimus, laaja.](http://www.huslab.fi/Tutkimusohjekirja%20haulla%20helikobakteeri:20609%20fP-Mabi-La%20fP-Mahalaukun%20biomerkkiainetutkimus,%20laaja)
38. [www.biohithealthcare.com / News/Links: Dear Colleague 2006](http://www.biohithealthcare.com/News/Links:Dear%20Colleague%202006)
39. Sipponen P, Härkönen M, Salaspuro M. Atrofinen gastriitti, Biomerkkiainetutkimus ja atrofinen gastriitti – tärkeä mahalaukun syövän ja B12 vitamiinipuutoksen riskitila. *Yksityislääkäri* 2008;308:91-98. [www.google.com /haulla atrofinen gastriitti: Atrofinen gastriitti – Terveystsa.](http://www.google.com/haulla%20atrofinen%20gastriitti:Atrofinen%20gastriitti-Terveystsa)
40. Storskrubb T, Aro P, Ronkainen J, Sipponen P, Nyhlin H, Talley NJ, Engstrand L, Stolte M, Vieth M, Walker M and Agréus L. Serum biomarkers provide an accurate method for diagnosis of atrophic gastritis in a general population: The Kalixanda study. *Scand J Gastroenterol* 2008; 43:1448-1455.
41. <https://www.biohithealthcare.com/wp-content/uploads/2020/04/GastroPanel-innovation.pdf>

Biohit Oyj

Laippatie 1, 00880
Helsinki, Finland

Puh. +358 9 773 861
info@biohit.fi

www.biohithealthcare.com
www.gastropanel.com
www.colonview.com
www.acetium.com

BIOHIT HealthCare
Innovating for Health